

**PATIENT**

Brody Permuy

**SPECIES**

Canine

**BREED**

Shepherd Mix

**SEX**

MN

**AGE**

8 years

**WEIGHT**

42 #

**INTERPRETED BY**

Remo Lobetti, BVSc,  
MMedVet (Med), PhD,  
Dipl. ECVIM

**IMAGING PERFORMED BY**

Lara Wiseman, DVM

**HOSPITAL NAME**

Village Royale Animal  
Clinic

**REFERRING VET**

**INVOICE**

303821

**DATE**

1/27/23

**PRESENTING CLINICAL SIGNS**

History: Vomiting, hyporexia, ADR.

Physical Examination: N/A.

Urinalysis: N/A.

CBC: N/A

Serum Biochemistry: N/A.

Radiographic Findings: N/A.

**ULTRASONOGRAPHIC EXAMINATION OF THE ABDOMEN**

**Urinary System**

Full urinary bladder with a normal thickness and appearance of the wall. Normal anechoic urine with no sediment or uroliths evident.

Normal trigone area, proximal urethra, and iliac blood vessels.

Normal iliac lymph nodes (1.4 cm). Ureters not visualized.

Normal renal size (left 5.8 cm, right 6.6 cm), echogenic appearance, cortico-medullary differentiation, pelvis, and capsule.

**Reproductive System**

Small hypoechogenic prostate (0.8 cm).

**Adrenal Glands**

Normal shape, echogenic appearance, position, and size. Left 0.63 cm, right 0.68 cm.

**Spleen**

Enlarged with an increased and coarse echogenic appearance. Smooth homogenous parenchyma, regular curvilinear capsule, and normal vasculature. No evidence of inflammatory, neoplastic, infarction, or infiltrative changes noted.

**Liver**

Normal size, echogenic appearance, portal markings, and regular curvilinear capsule. No nodules or masses evident. Full gall bladder normal anechoic bile. Normal thickness and appearance of the gall bladder wall. Normal bile duct.

**Gastrointestinal**

Normal appearance of the gastro-esophageal junction, stomach, duodenum, small intestine, ileo-cecal junction, and colon with no loss of layering, normal wall thickness (duodenum 0.45 cm, jejunum 0.36 cm) and peristalsis, and no distension of the lumen.



**PATIENT**

Brody Permuy

**SPECIES**

Canine

**BREED**

Shepherd Mix

**SEX**

MN

**AGE**

8 years

**WEIGHT**

42 #

**INTERPRETED BY**

Remo Lobetti, BVSc,  
MMedVet (Med), PhD,  
Dipl. ECVIM

**IMAGING PERFORMED BY**

Lara Wiseman, DVM

**HOSPITAL NAME**

Village Royale Animal  
Clinic

**REFERRING VET**

**INVOICE**

303821

**DATE**

1/27/23

***Pancreas***

Normal size (right 1.1 cm) and echogenic appearance. Regular capsule. Normal echogenic appearance of the mesentery and fat surrounding the pancreas.

***Free Abdomen***

No mesenteric lymphadenomegaly.

Hepatic lymphadenomegaly (1.5 x 4.6 cm) with a rounded and hypoechogenic appearance. Small amount of ascites around the liver.

**ULTRASONOGRAPHIC FINDINGS**

Primary findings:

- Splenomegaly.
- Hepatic lymphadenomegaly.
- Ascites.

Secondary findings:

- None.

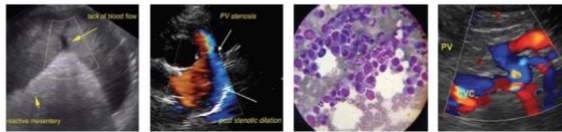
**INTERPRETATION OF THE FINDINGS & FURTHER RECOMMENDATIONS**

Etiologies for the spleen and lymph node would be reactive, splenitis/lymphadenitis, and neoplasia.

The ascites can be ascribed to the splenomegaly and lymphadenomegaly.

Further assessment would CBC, 4Dx/PCR for vector-borne disease, 3-view thoracic radiographs, and FNA cytology of the spleen and lymph node.

Specific therapy would be dependent on an etiological diagnosis.



**PATIENT**

Brody Permuy

**SPECIES**

Canine

**BREED**

Shepherd Mix

**SEX**

MN

**AGE**

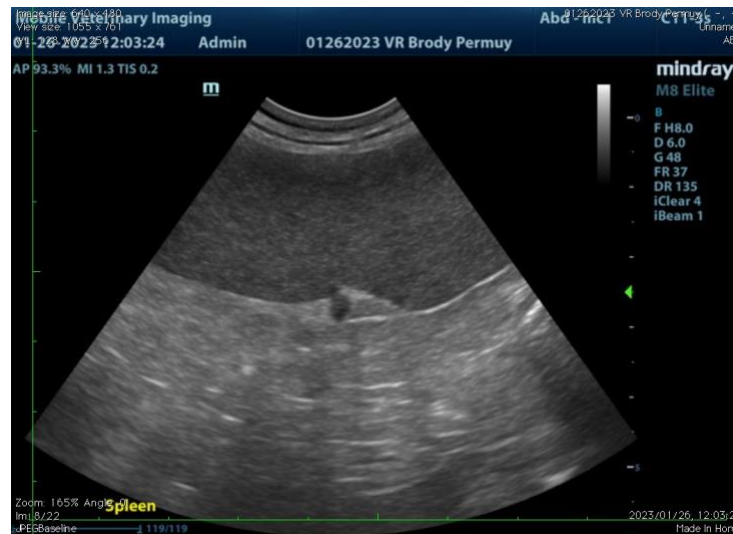8 years

**WEIGHT**

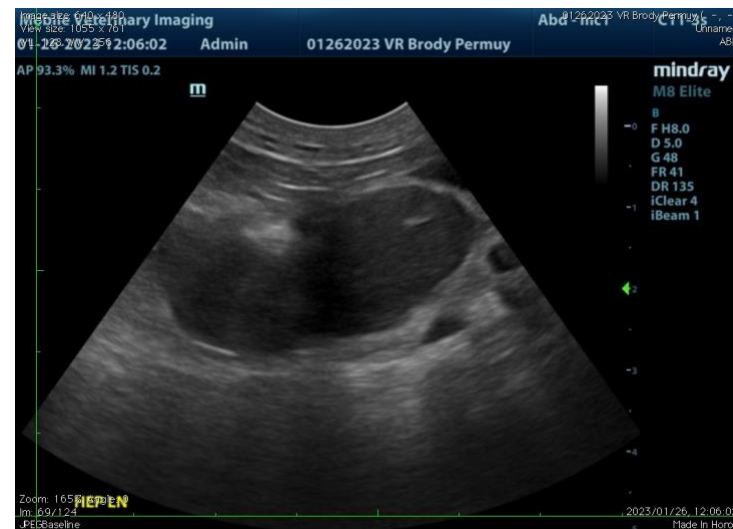42 #

**IMAGES**

**Spleen**



**Hepatic lymph node**



**INTERPRETED BY**

Remo Lobetti, BVSc,  
MMedVet (Med), PhD,  
Dipl. ECVIM

**IMAGING PERFORMED BY**

Lara Wiseman, DVM

**HOSPITAL NAME**

Village Royale Animal  
Clinic

**REFERRING VET**

**INVOICE**

303821

**DATE**

1/27/23

The information and recommendations provided are based on the images presented by the referring veterinarian. No evaluation can be communicated regarding pathology that was not visible in the image/video clips provided.

Thank you for this referral. If the clinical or image interpretation does not parallel your findings or if I can be of any further assistance please contact me.

**Remo Lobetti, BVSc, MMedVet (Med), PhD, Dipl. ECVIM (Internal Medicine)**  
rlobetti@mweb.co.za